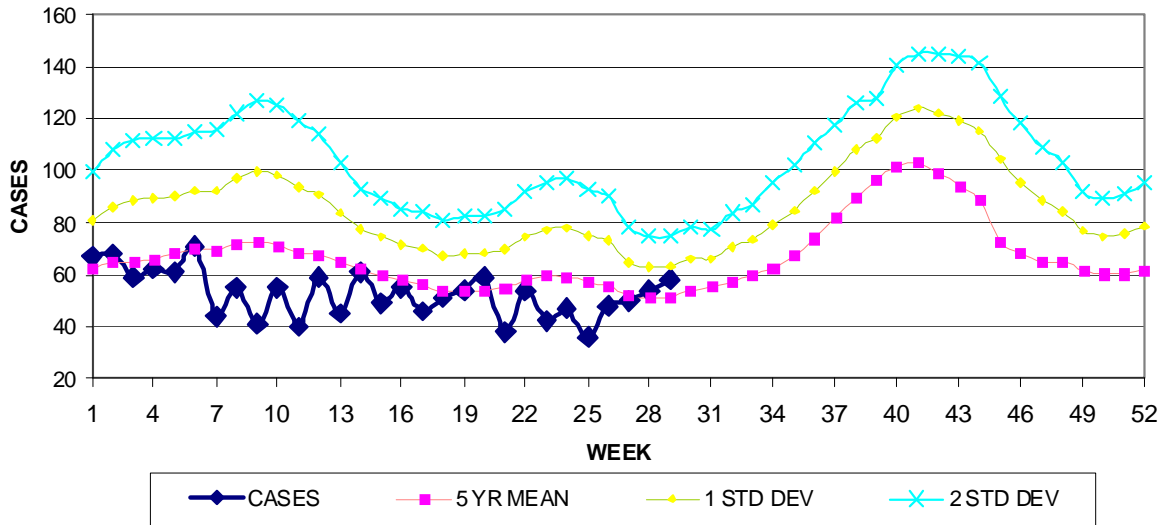


GUAM EPIDEMIOLOGY NEWSLETTER

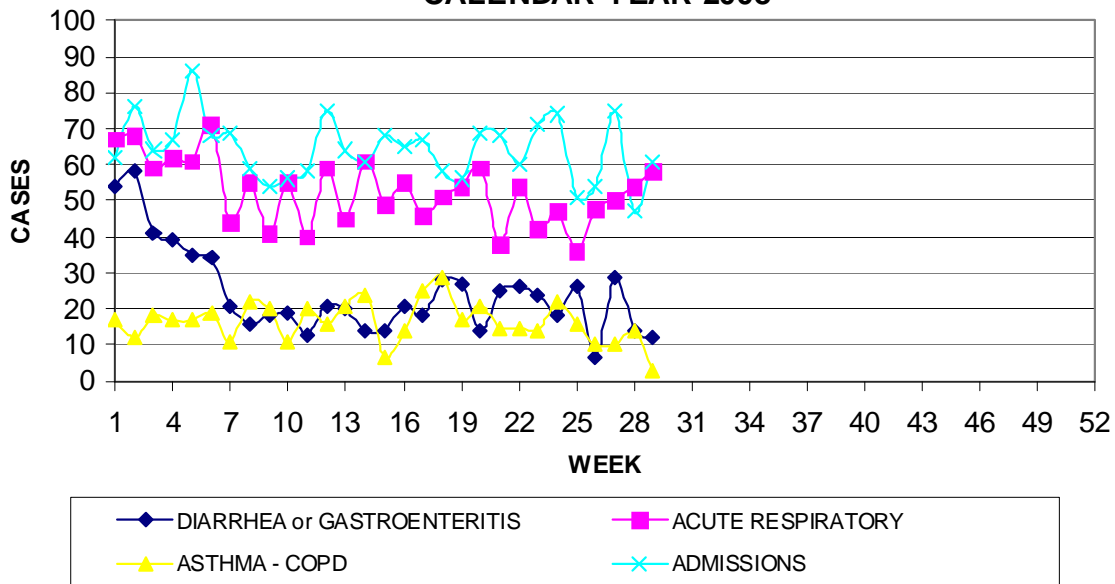
REPORT FOR WEEK ENDING: 7/19/2008 (Reporting week 2008-29)

GUAM REPORTS

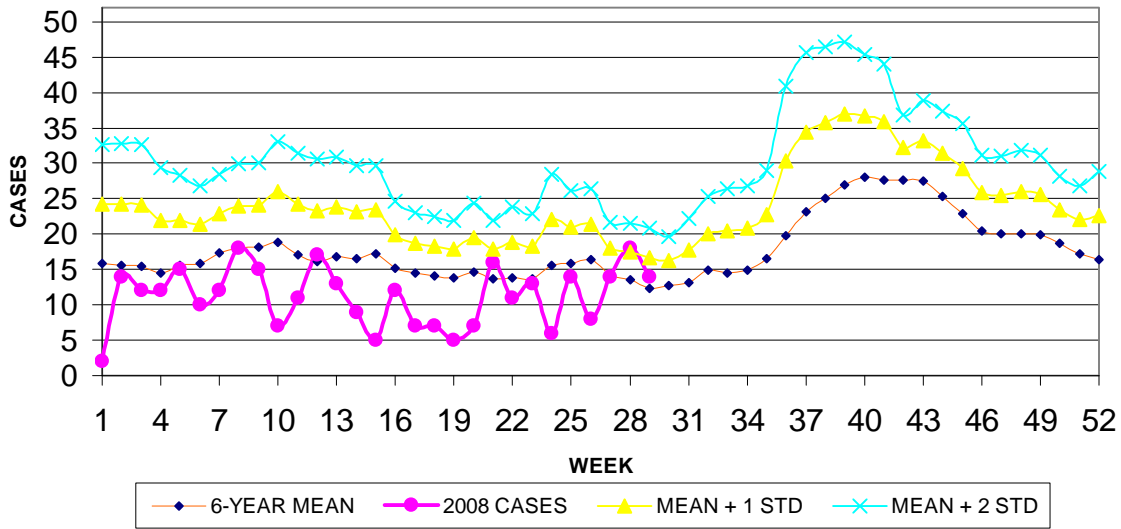
**GUAM ACUTE RESPIRATORY INFECTION SURVEILLANCE, 2008;
 NUMBER OF PATIENTS SEEN IN THE GMHA-ED BY WEEK SEEN**



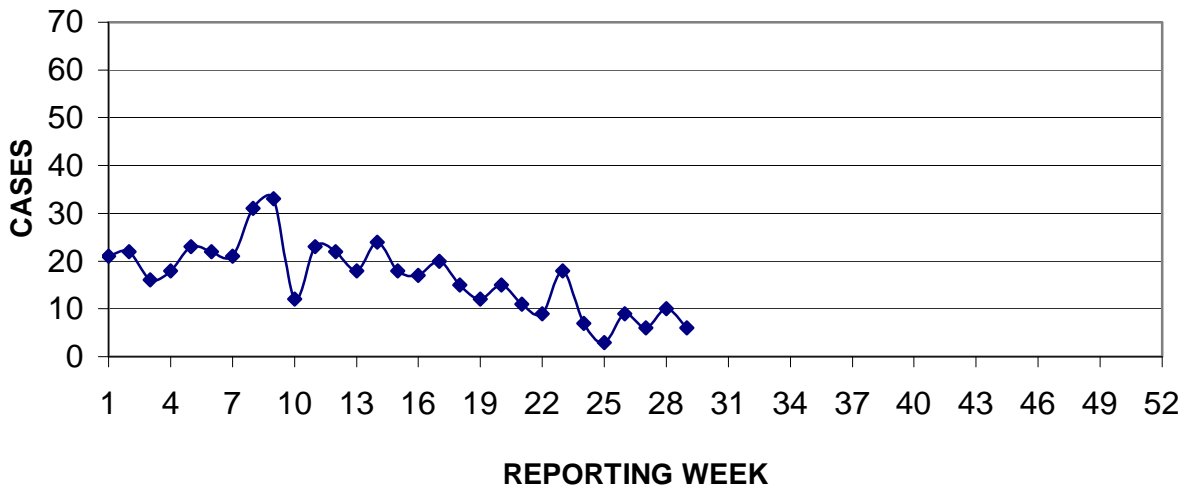
**GUAM SYNDROMIC DISEASE SURVEILLANCE
 GMHA-ED PATIENT DIAGNOSES BY WEEK FOR
 CALENDAR YEAR 2008**



MEDICAL RECORDS DEPARTMENT
 GUAM MEMORIAL HOSPITAL AUTHORITY
**HOSPITAL INPATIENT DISCHARGES WITH A DIAGNOSIS OF
 PNEUMONIA BY WEEK DISCHARGED, 2008**



PREVENTIVE MEDICINE DEPARTMENT
 U.S. NAVAL HOSPITAL GUAM
**PNEUMONIA CASES SEEN IN GUAM MILITARY TREATMENT FACILITIES
 BY WEEK REPORTED, 2008**



GUAM COMMUNICABLE DISEASE REPORT

REPORTS ENTERED DURING MORBIDITY WEEK 29
(REPORTS FROM ALL SOURCES, INCLUDING MILITARY CLINICS -
SOME CASES MAY REPRESENT DELAYED REPORTS)

DISEASE	2008	2007
CAMPYLOBACTER	0	1
CHICKENPOX	2	15
<i>Clostridium difficile</i>	0	1
CONJUNCTIVITIS	3	11
FOOD POISONING	3	0
GONORRHEA	1	0
HERPES SIMPLEX 2	1	0
MALARIA	0	1*
MRSA	3	5
SALMONELLOSIS	2	1
STREP SORE THROAT	7	14
STREP DISEASE, OTHER	1	0

* Imported case contracted in Philippines

GUAM SENTINEL PHYSICIAN INFLUENZA SURVEILLANCE

REPORTS RECEIVED FOR THE WEEK ENDING 7/19/2008
NO ACTIVITY (NO CASES REPORTED)

GUAM ANIMAL DISEASE (ZONOSSES) REPORTS

REPORTS RECEIVED FOR THE WEEK ENDING 7/19/2008
NONE REPORTED

SPECIAL REPORT : Tick-borne diseases, a threat to Guam?

A Guam veterinarian has reported observing a number of cases of anaplasmosis and babesiosis in local dogs and anaplasmosis has previously been reported in Guam cattle and carabao. To our knowledge no cases of locally-acquired human rickettsial infections have been diagnosed on Guam but their presence in local animals suggests that this may be a possibility (Lyme disease has been diagnosed in Guam residents returning from travel in the U.S. and Palau has experienced an outbreak of scrub typhus) . The following is a brief summary of some tick or mite-borne diseases that could occur on Guam. Patients are likely to present with a fever of unknown origin, Guam physicians are encouraged a seek laboratory confirmation if they see patients with appropriate symptoms and without another likely diagnosis (cases of leptospirosis, for instance, may have a similar presentation). Once diagnosed, consultation with an infectious disease specialist for latest treatment options would be appropriate.

ANAPLASMOSIS Human anaplasmosis (HA), formerly known human granulocytic ehrlichiosis (HGE), is a bacterial disease transmitted to humans by *Ixodes scapularis* (deer tick or blacklegged tick), the same tick that transmits Lyme disease. The HA agent was recently named *Anaplasma phagocytophilum* and was believed to be similar or identical to two veterinary pathogens, *Ehrlichia equi* and *Ehrlichia phagocytophila*. A human monocytic form of ehrlichiosis caused by *Ehrlichia chaffeensis* is found throughout much of southeastern and south-central United States.

Signs and Symptoms: Onset of illness occurs 1 to 3 weeks after exposure to an infected tick. Common signs and symptoms include fever (often over 102°F), chills, headache, and myalgias. Nausea, vomiting, anorexia, acute weight loss, abdominal pain, cough, diarrhea, and change in mental status are reported less frequently. Highly suggestive laboratory findings include leukopenia (WBC < 4,500/mm³), thrombocytopenia (platelets < 150,000/mm³), and increased aminotransferase levels.

Diagnosis: Use of any two of the following tests have been recommended for evidence of infection with *Anaplasma phagocytophilum*: 1) An indirect immuno-fluorescence assay (IFA) is the principal test used to detect HA infection. Acute and convalescent phase serum samples can be evaluated to look for a four-fold change in antibody titer to HA. 2) Intracellular inclusions (morulae) may be visualized in granulocytes of Wright- or Giemsa-stained blood. 3) Polymerase chain reaction (PCR) assays are being used increasingly to detect HA DNA.

BABESIOSIS *Babesia microti* is a protozoan of the piroplasm family most commonly transmitted by the bite of nymphal *Ixodes* ticks..

Signs and symptoms: The clinical spectrum ranges from mild and self-limited to serious. Severe infections are most common in patients who have had a splenectomy or are otherwise immunosuppressed. A gradual onset of illness may include: malaise, anorexia, and fatigue followed by fever, chills, myalgias, arthralgias, nausea and vomiting. Hypotension and renal failure have been reported. Thrombocytopenia, hemolysis, and hepatic dysfunction may be present.

Diagnosis: In acutely ill patients, careful examination of blood smears by experienced individuals usually reveals intraerythrocytic parasites. Other tests include polymerase chain reaction (PCR) and indirect immunofluorescence assay (IFA).

LYME DISEASE Caused by *Borrelia burgdorferi*, a spirochete transmitted by the bite of *Ixodes* ticks.

Signs and symptoms: The early signs and symptoms of Lyme disease are ambiguous, patients may complain that they feel like they have "the flu."

- **Early symptoms (3 to 30 days after a tick bite):** rash, fever, chills, headache, muscle and joint pain, fatigue.
- **Days to weeks later:** multiple rashes, one-sided facial paralysis, fever, stiff neck, headache, weakness, numbness or pain in arms or legs, irregular heart beat, persistent weakness and fatigue.
- **Weeks to months later:** arthritis in one or more joints, usually the knees, nervous system disorders, persistent weakness and fatigue

Diagnosis: IFA, ELISA, confirmation with Western Blot.

ROCKY MOUNTAIN SPOTTED FEVER Caused by *Rickettsia rickettsii*, transmitted by *Dermacentor variabilis* (wood tick).

Signs and symptoms: Abrupt onset of fever, malaise, headache, myalgias, nausea and vomiting, and a rash. The typical rash first appears as macules on the wrists and ankles which then spread to the trunk, face, palms, and soles. Thrombocytopenia, increased serum hepatic aminotransferase levels, and hyponatremia may be present.

Diagnosis: PCR

SCRUB TYPHUS Caused by *Orientia* (formerly *Rickettsia*) *tsutsugamushi*, an obligate intracellular gram-negative bacterium, transmitted by the larval stage of a trombiculid mite (chigger).

Signs and symptoms: Abrupt onset of high fever (104-105°F), severe headache, myalgia, and eschar (resembling a cigarette burn) with tender regional lymphadenopathy. Albuminuria, early lymphopenia with late lymphocytosis. Less frequently, ocular pain, wet cough, malaise, and injected conjunctiva are present. Toward the end of the first week, approximately 35% of patients develop a centrifugal macular rash on the trunk, which may become papular. By this time, hepatosplenomegaly and generalized lymphadenopathy are present. A small number of patients have CNS involvement, with tremors, nervousness, slurred speech, nuchal rigidity, or deafness during the second week of the disease; however, results from the cerebrospinal fluid examination either are normal or indicate a low number of monocytes.

Diagnosis: Indirect immunoperoxidase test, an immunofluorescent assay or PCR. An infection is confirmed by a 4-fold increase in antibody titers between acute and convalescent serum specimens. A single high titer with classic clinical features is considered a probable case. A dot immunoassay has also been used in the serodiagnosis of scrub typhus.